Aesthetic Refinements in the Treatment of Graves Ophthalmopathy

Gaby Doumit, M.D., M.Sc.
William Abouhassan, M.D.
Michael J. Yaremchuk, M.D.

Cleveland and Cincinnati, Ohio; and Boston, Mass.

Background: Graves ophthalmopathy is a chronic, multisystem, autoimmune disorder characterized by increased volume of intraorbital fat and hypertrophic extraocular muscles. Proptosis, impaired ocular motility, diplopia, lid retraction, and impaired visual acuity are treated with orbit decompression and fat reduction. The authors present the addition of skeletal augmentation to further improve periorbital aesthetics.

Methods: Through a transconjunctival with lateral canthotomy incision, a balanced orbital decompression was executed, removing medial and lateral walls and medial floor. Intraorbital fat was excised. All patients underwent placement of porous polyethylene infraorbital rim implants and midface soft-tissue elevation, increasing inferior orbital rim projection and improving the globe-cheek relationship. From 2009 to 2012, 13 patients (11 female and two male; 26 eyes) with Graves ophthalmopathy underwent surgery at two institutions. Outcomes were evaluated for improvements of proptosis, diplopia, dry eye symptoms, and cosmetic satisfaction.

Results: Postoperative follow-up ranged from 0.5 to 3 years (median, 1.5 years). The mean improvement on Hertel exophthalmometry was 5.4 mm. Diplopia resolved in three patients (23 percent). No patients had worsening diplopia, and 12 (92 percent) discontinued use of eye lubricants. All patients had cosmetic satisfaction. One patient suffered temporary inferior orbital nerve paresthesia. There were no infections, hematomas, or ocular complications.

Conclusions: Skeletal augmentation is a useful adjunct to orbital decompression and fat excision for treating Graves ophthalmopathy. Balanced orbital decompression with infraorbital rim implants is reliable, effective, and safe, with good, lasting results. Resolution of ocular symptoms is improved, as are the patient's personal well-being and social life, with a high-benefit–to–low-risk. (*Plast. Reconstr. Surg.* 134: 519, 2014.)

CLINICAL QUESTION/LEVEL OF EVIDENCE: Therapeutic, IV.

Graves disease is a chronic, multisystem disorder characterized by hyperthyroid goiter, tachycardia, ophthalmopathy and, rarely, dermopathy caused by an autoimmune process. In his 1991 sentinel article, Olivari described three key objective findings in Graves ophthalmopathy: retraction of the upper lid on downward gaze, proptosis/exophthalmos, and disturbance of eye motility, which in high-grade endocrine ophthalmopathy progresses to diplopia.[1] Graves ophthalmopathy may also be associated with the following clinical findings: hypertrophy and fibrosis of the extraocular muscles (leading to diplopia and ophthalmoplegia), eyelid edema, conjunctivitis, photophobia, chemosis, lagophthalmos, tearing, keratitis, upper and lower eyelid retraction, corneal ulceration resulting from the inability to close the eyelid,

From the Department of Plastic Surgery, Institute of Dermatology and Plastic Surgery, Cleveland Clinic; the Division of Plastic, Reconstructive & Hand/Burn Surgery, Department of Surgery, University of Cincinnati School of Medicine; and the Division of Plastic and Reconstructive Surgery, Department of Surgery, Massachusetts General Hospital.
Received for publication February 5, 2013; accepted May 13, 2013.
Presented at the 55th Annual Meeting of the Ohio Valley Society of Plastic Surgeons, in Cleveland, Ohio, May 18 through 19, 2012.

DOI: 10.1097/PRS.0000000000000453

Disclosure: *The authors have no financial interest to declare in relation to the content of this article. No external funds were received.*

headache, retrobulbar pain, glaucoma, optic neuropathy caused by the increased intraorbital pressure,[2] and prominent glabellar rhytides.[3] However, not only does Graves ophthalmopathy lead to visual problems, it also has a major impact on daily functioning and well-being. The psychological burden of progressive disfigurement resulting from Graves ophthalmopathy is well recognized.[4] Surgical treatment of Graves ophthalmopathy not only alleviates ocular symptoms, but in so doing, also improves the periocular appearance. Our recommendation for timing of surgical intervention requires that all patients be euthyroid for a minimum of 6 months before any orbital surgery.

As a result of the chronic fibrosis significant of Graves ophthalmopathy, patients typically have upper lid retraction, particularly on downward gaze, involving the levator aponeurosis and upper lid skin. Lower lid retraction and descent are common in these patients as well, because of the similar pathophysiology of chronic fibrosis. In our series, a subset of these patients underwent upper eyelid correction by oculoplastic surgery before being referred to our service. The midface lift and lateral canthoplasty, intrinsic to our surgical approach, is meant to correct the lower lid maladies. Following decompression, patients with persistent upper lid retraction underwent sectioning of the levator aponeurosis with the addition of a müllerectomy where indicated. Augmentation of the infraorbital rim with cheek resuspension further improves globe-rim relations, thereby further refining periorbital aesthetics.

PATIENTS AND METHODS

This study was conducted in accordance with the principles outlined in the Declaration of Helsinki. A lower eyelid transconjunctival incision is performed. A retroseptal dissection is carried through the right lower eyelid. A 7-mm lateral canthal incision is made and the lateral canthus is then released. The arcus marginalis is divided and a subperiosteal orbital dissection is carried for 270 degrees from the medial to lateral wall of the orbit. The midface is also degloved through the transconjunctival incision. The infraorbital nerve is identified and protected. Using a TPS burr (Stryker, Kalamazoo, Mich.), the lateral orbital wall is removed from posterior to the orbital rim back to its junction with the middle cranial fossa. A periosteal elevator is used to infracture the medial wall of the orbital and its ethmoid air cells (Fig. 1). The medial, central, and lateral orbital fat pads are then partially excised.

An inferior orbital rim implant (Medpor; Porex Surgical, Inc., Newnan, Ga.) (Fig. 2) is then inserted through the lower eyelid incision. Two screws are used to fix the implant in place. The same process is repeated on the contralateral side.

The midface soft tissues are elevated in a subperiosteal plane and sutured to the rim implant at the level of the pupil and lateral canthus. A lateral canthoplasty is performed by suspending the lateral canthus ligament to the Whitnall tubercle or to the zygomaticofrontal suture. A lateral temporary tarsorrhaphy is performed to control postoperative chemosis. Representative cases are shown in Figures 3 and 4.

Statistical Analysis

Frequency was used to summarize the categorical variables of dry eye versus no dry eye symptoms. A McNemar test was used to test associations

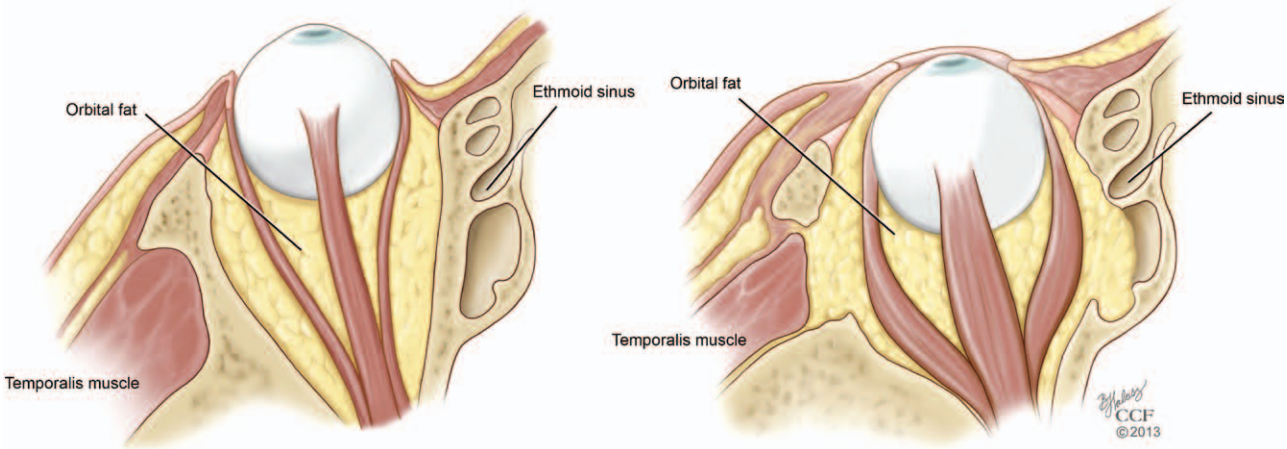

Fig. 1. Preoperative and postoperative illustrations demonstrating medial and lateral orbital wall expansion. (Printed with permission from Gaby Doumit, M.D., MSc.)

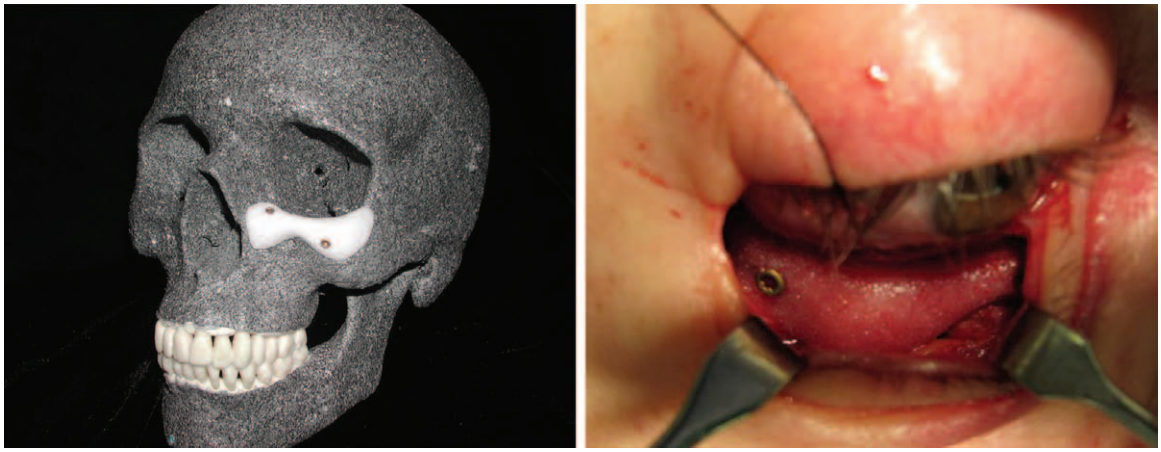

Fig. 2. (*Left*) Porous polyethylene left inferior orbital rim implant, fixed in its anatomical position to a skull model with two screws. (*Right*) Intraoperative photograph demonstrating the position and fixation of a right inferior orbital rim implant.

between these two categorical variables. A value of $p < 0.05$ was considered significant. The analysis was performed using SAS 9.2 (SAS Institute, Inc., Cary, N.C.). Assessment of postoperative satisfaction was made by interviewing the patient during follow-up and recording the level of satisfaction reported.

RESULTS

Thirteen patients (26 eyes) with Graves ophthalmopathy were treated with the aforementioned technique at two institutions (Massachusetts General Hospital and Cleveland Clinic) over a 4-year period (2009 to 2012). All patients underwent similar procedures whereby orbital fat was removed, three-wall orbital decompressions were performed, infraorbital rim implants were placed, and a subperiosteal midface lift was conducted. These maneuvers were carried out through transconjunctival incisions of the lower lid with an extension into a lateral canthotomy and occasionally an upper gingivobuccal sulcus incision.

Patients were followed from 6 to 36 months postoperatively, with a median follow-up of 18 months. There was a mean Hertel exophthalmometer improvement of 5.42 mm (range, 4.9 to 6.0 mm). Diplopia resolved in three of 13 cases (23 percent), and no patient had worsening diplopia. Twelve of 13 patients (92 percent) discontinued use of eye lubricants. The McNemar test revealed a value of $p < 0.001$, which is considered statistically significant and infers significant improvement in the symptom of dry eyes from the preoperative to postoperative state. Patients were asked about their satisfaction with the operation postoperatively. All patients had cosmetic satisfaction and reported high levels of fulfillment. One patient suffered temporary paresthesia to the infraorbital nerve. No infections, hematomas, or ocular complications were reported. Table 1 demonstrates our patients' improvements in exophthalmos, based on their change in Hertel measurements.

DISCUSSION

Graves ophthalmopathy is a chronic autoimmune condition that usually affects both orbits and involves all orbital tissue compartments, including the extraocular muscles, periorbital connective/fatty tissue, and lacrimal gland. The clinical signs and symptoms of Graves ophthalmopathy reflect the mechanical consequences of increased orbital tissue volume and pressure within the orbit.[5] These consequences lead to an abnormal and symptomatic protrusion of the globes from the orbits of patients. Clinical findings are proptosis, impaired ocular motility, diplopia, lid retraction, and impaired visual acuity up to optic neuropathy, with menacing blindness. The addition of skeletal augmentation to orbit decompression and fat reduction treats symptoms and improves periorbital aesthetics.

Normal globe protrusion varies between sexes and races (Table 2), as measured by the Hertel exophthalmometer. When a difference of greater than 1.5 mm exists between globes on the same individual, this is considered abnormal. A gross examination of the orbital tissues in patients with active Graves ophthalmopathy reveals edematous, enlarged extraocular muscle

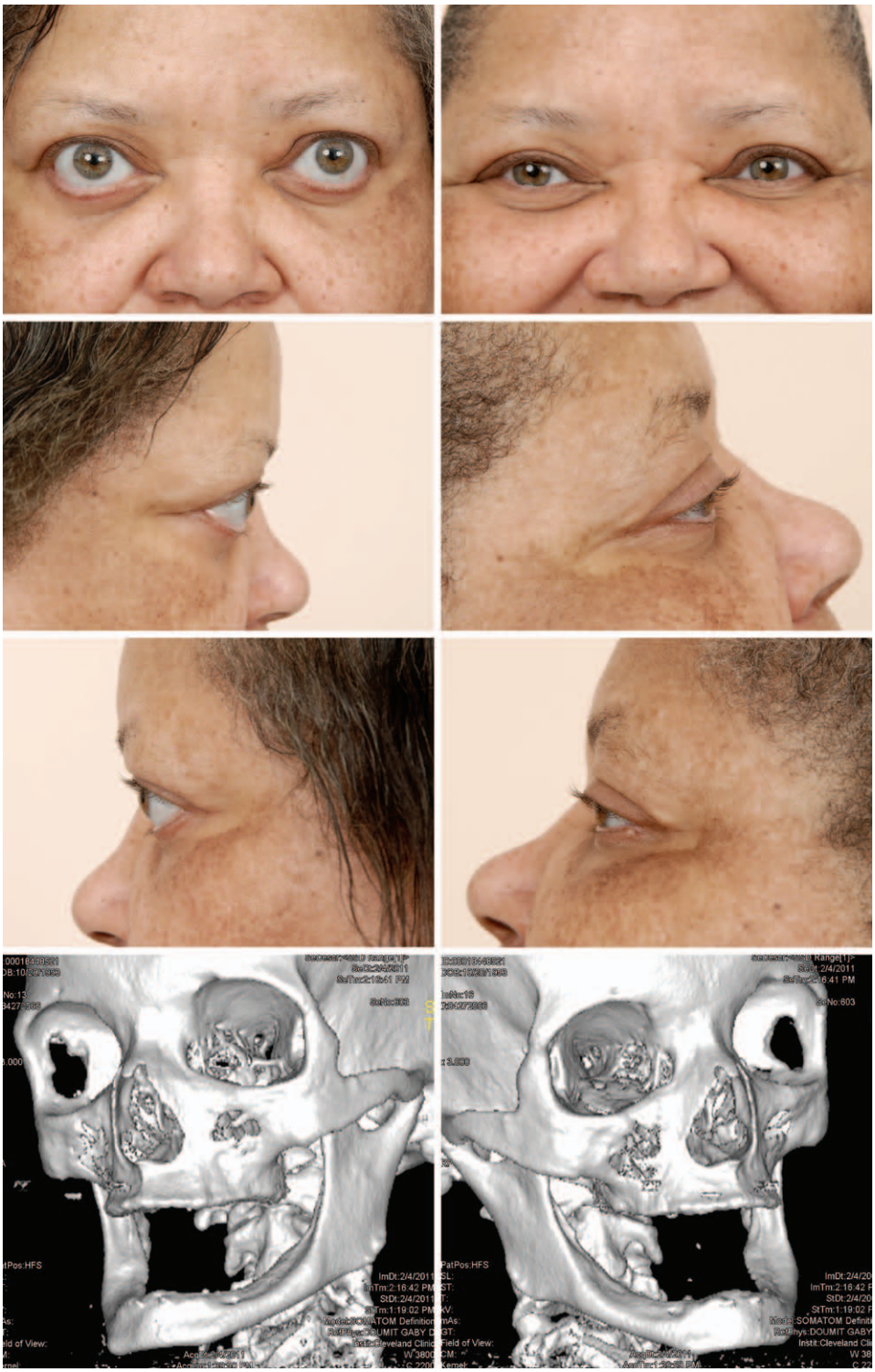

Fig. 3. Case 1. A 57-year-old woman presented with bilateral dry eyes, epiphora, and progressive prominent eyes. The patient's medical history is positive for Graves disease and unrepaired left orbital floor fracture. Preoperative and 12-month postoperative Hertel exophthalmometer measurements were 25 mm (right eye) and 24 mm (left eye), and 20 mm (right eye) and 19 mm (left eye), respectively. (*Above*, *left* and *second and third rows*, *left*) Preoperative frontal and profile views. (*Above*, *right* and *second row and third rows*, *right*) Twelve-month postoperative frontal and profile views. (*Below*) Postoperative three-dimensional computed tomographic scans demonstrating the orbital wall decompressions.

Fig. 4. Case 2. A 56-year-old woman presented with disturbing Graves ophthalmopathy and epiphora. Preoperative and 18-month postoperative Hertel exophthalmometer measurements were 27 mm (right eye) and 26 mm (left eye), and 21 mm (right eye) and 21 mm (left eye), respectively. (*Left*) Preoperative frontal and profile views. (*Right*) Eighteen-month postoperative frontal and profile views.

bodies in conjunction with an increase in orbital connective and fatty tissue volumes. The orbital inflammatory process is also likely to be driven by T cells that, in response to a yet uncertain antigen, access and infiltrate the orbital space through their interaction with several adhesion molecules.[5]

Once the disease has progressed, many various clinical signs, such as proptosis, extraocular muscle dysfunction, periorbital and lid edema, conjunctival congestion, and chemosis, can be explained mechanically by the increase in connective/fatty tissue and extraocular muscle volume within the boundaries of the bony orbits.[6] Many surgical techniques have been described to relieve the orbital symptoms. Tessier[7] advocated moving three walls by impacting the medial orbital wall, lowering the floor, and including a valgus osteotomy of the lateral orbital wall. Wolfe[8] modified the Tessier technique by changing the

Table 1. Patients' Improvements in Exophthalmos Based on Changes in Hertel Exophthalmometric Measurements

Patient	Mean Improvement on Hertel Exophthalmometry (mm)
1	5.4
2	5
3	5.9
4	5.7
5	5.1
6	5.2
7	5.7
8	5.5
9	5.3
10	4.9
11	6
12	5.5
13	5.2
Mean	5.42
Median	5.4
Range	4.9–6
SD	0.341189473

Table 2. Normal Globe Protrusion*

	Protrusion (mm)
Black men	18.5
Black women	17.8
White men	16.5
White women	15.4

*Difference between orbits of >1.5 mm is abnormal.

direction of the lower osteotomy line to avoid posterior displacement of the lateral orbital wall. The major complication was an inadequate correction of the exophthalmos in two of 10 patients. Leong et al.[9] report clear surgical indications for operating on "dysthyroid orbitopathy." Patients who fit the indications describe a substantial majority (83 percent) having disfiguring exophthalmos (42.4 percent) or optic nerve compression (40.6 percent). A subset of patients with optic nerve compression displayed hypertrophic extraocular muscles at the orbital apex with edematous fat. Extreme cases of optic neuropathy with loss of site was also reported (<5 percent). A third indication reported by Leong et al. is that of corneal exposure (8 percent) and its symptoms.

We take a three-tier progressive approach in our experience with patients suffering from Graves ophthalmopathy: intraorbital fat removal, orbital wall removal, and facial skeletal augmentation. Isolated intraorbital fat removal is performed on patients with mild proptosis. It is typically reserved for those cases where primarily fat is involved. The approach is through both lower and upper eyelid incisions. Removing fat volumes between 3 and 6 ml will lead to a correction of exophthalmos between 3 and 6 mm. Orbital wall removal is performed on patients with moderate to severe proptosis. Orbital expansion is the best technique in cases of muscular enlargement and optic neuropathy. Osseous expansion can be performed by means of two- or three-wall removal. Removal of the medial and lateral wall (a balanced orbital decompression) reduces the incidence of postoperative strabismus. Shifting orbital fat tissue medially and laterally into the surgically created periorbital spaces retrudes the globe by diminishing the amount of orbital fat tissue located posterior to the globe. In cases of moderate to severe proptosis, favoring severity

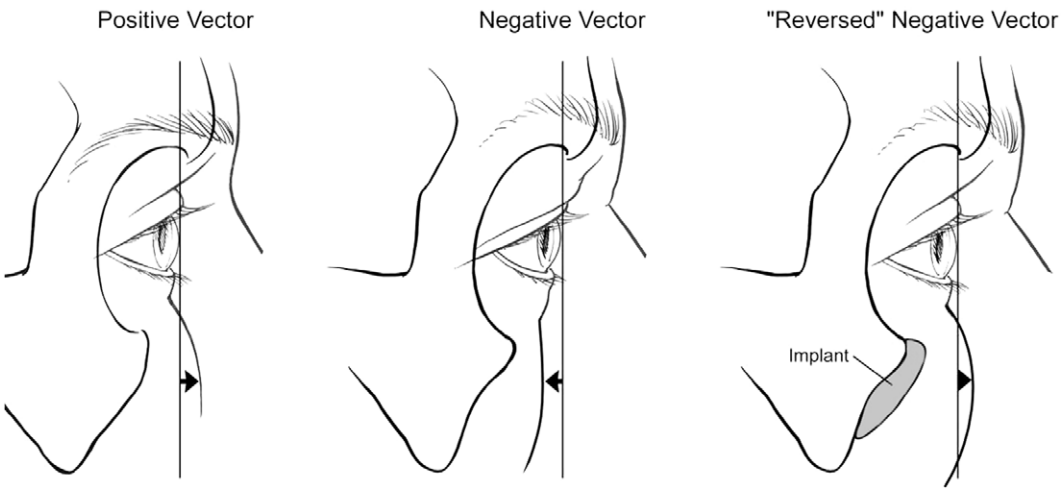

Fig. 5. Anterior cornea to malar prominence relationship. (Reprinted with permission from Dr. Michael J. Yaremchuk from: Yaremchuk MJ. *Atlas of Facial Implants.* Philadelphia: Saunders-Elsevier; 2007.)

CODING PERSPECTIVE

This information provided by Dr. Raymond Janevicius is intended to provide coding guidance.

67414	Orbitotomy without bone flap (frontal or transconjunctival approach); with removal of bone for decompression
14061-51	Midface soft tissue advancement, 10.1 - 30 square centimeters

- The decompression of the orbit is reported with code 67414.
- Code 67414 includes the transconjunctival approach, bone removal, and reconstruction.
- The soft tissue rearrangement of the lower eyelid and midface is reported as an adjacent tissue transfer and is coded by total surface area. If the total surface area exceeds 10 square centimeters, report 14301.
- For bilateral procedures report

  67414-50
  14061-51
  14061-59

- Although bilateral midface soft tissue advancements are performed, 14061 is not considered a "bilateral" procedure by CPT rules, so modifier 50 is not appended (as it is for code 67414). Modifier 59 is used with code 14061.
- Some insurance companies will not reimburse for Graves reconstruction unless certain specific criteria are met. Always preauthorize these procedures, ***in writing***, prior to performing the surgery.

(when the relationship of the anteriormost point of the cornea to the malar eminence is of a significant negative vector, as in Fig. 5, *left*), augmentation of the craniofacial skeleton with implants is used. This negative vector relationship contributes to the ocular symptoms in Graves ophthalmopathy previously described. Ultimately, the goal is to establish a positive vector (Fig. 5, *center*).

With the addition of craniofacial skeletal augmentation and a subperiosteal midface lift at the malar eminence, we have established the so-called reversed negative vector (Fig. 5, *right*). The establishment of the reversed negative vector is a combination of both intraorbital and extraorbital surgical techniques that have proven to be of substantial symptomatic relief and improved periocular appearance for patients suffering from severe Graves ophthalmopathy.

CONCLUSIONS

Graves ophthalmopathy is a very complex disorder. Each patient requires a personalized approach, which is why no standardized protocol exists. The choice of treatment depends greatly on the soft-tissue and muscular components of the patient's condition; how advanced the disease is at the time of presentation; the constellation of symptoms the patient presents with; and the surgeon's background, experience, and knowledge of major surgical techniques. Skeletal augmentation is a useful adjunct to orbital decompression and fat excision for treating Graves ophthalmopathy. The combination of balanced orbital decompression and infraorbital rim implants has proven to be reliable, effective, and safe, with good, lasting results. Improvements are made toward the resolution of ocular symptoms and in the patient's personal well-being and social life, with a high-benefit–to–low-risk ratio.

William Abouhassan, M.D.
Department of Surgery
Division of Plastic, Reconstructive & Hand/Burn Surgery
University of Cincinnati College of Medicine
231 Albert Sabin Way
P.O. Box 670558
Cincinnati, Ohio 45267-0558
william.abouhassn@uc.edu

PATIENT CONSENT

Patients provided written consent for the use of their images.

REFERENCES

1. Olivari N. Decompression of endocrine ophthalmopathy. *Plast Reconstr Surg.* 1991;87:627–641.
2. Richter DF, Stoff A, Olivari N. Transpalpebral decompression of endocrine ophthalmopathy by intraorbital fat removal (Olivari technique): Experience and progression after more than 3000 operations over 20 years. *Plast Reconstr Surg.* 2007;120:109–123.

3. Saks ND, Burnstine MA, Putterman AM. Glabellar rhytids in thyroid-associated orbitopathy. *Ophthal Plast Reconstr Surg.* 2001;17:91–95.
4. Terwee CB, Gerding MN, Dekker FW, Prummel MF, Wiersinga WM. Development of a disease specific quality of life questionnaire for patients with Graves' ophthalmopathy: The GO-QOL. *Br J Ophthalmol.* 1998;82: 773–779.
5. Clauser L, Galiè M, Sarti E, Dallera V. Rationale of treatment in Graves ophthalmopathy. *Plast Reconstr Surg.* 2001; 108:1880–1894.
6. Wiersinga WM, Bartalena L. Epidemiology and prevention of Graves' ophthalmopathy. *Thyroid* 2002;12:855–860.
7. Tessier P. Expansion chirurgicale de l' orbite. *Ann Chir Plast.* 1969;14:207–214.
8. Wolfe SA. Modified three-wall orbital expansion to correct persistent exophthalmos or exorbitism. *Plast Reconstr Surg.* 1979;64:448–455.
9. Leong SC, Karkos PD, Macewen CJ, White PS. A systematic review of outcomes following surgical decompression for dysthyroid orbitopathy. *Laryngoscope* 2009;119:1106–1115.

Evidence-Based Medicine: Questions and Answers

Q: What papers are amenable to Level of Evidence grading? What if my paper is not amenable to grading? Will *PRS* consider it for publication?

A: A good rule of thumb is as follows (these papers are not amenable to LOE grading):

- Animal studies
- Cadaver studies
- Basic science studies
- Review articles
- Instructional course lectures
- CME courses
- Editorials
- Correspondence

As far as what is or is not ratable, the standard is to exclude basic science, bench work, animal, and cadaveric studies because the information gained from these studies is not something that can be applied directly to patient treatment decisions.

PRS definitely welcomes such papers, and such papers will be considered for publication. As indicated above, the LOE grade is a number, a quantitative designation for data. Papers that cannot be graded for Level of Evidence grade are not "worse" than those that can be graded.